



Reg Charity 203644 (England and Wales) SC037711 (Scotland)

Ringworm Procedures

February 2013

1. What is ringworm?

Ringworm is not caused by a worm, but is the common name given to an infection of the surface of the skin, hair or nails with a type of fungus called a dermatophyte. There are many types of dermatophyte and the most common one that causes ringworm in cats is *Microsporum canis* (*M canis*); it is seen in over 90 per cent of cases. Other causes of ringworm in cats include *Trichophyton* species. Spores are the infectious stage of the dermatophyte and may be shed on the infected hairs of affected animals or people. These spores are very robust and can remain infectious in the environment, blown by the wind for up to two years.

Ringworm is contagious to people and other animals. Care must be taken when handling/dealing with infected cats as it is a **zoonotic disease** that can be passed from cats to people.

2. How is ringworm diagnosed?

Four tests are available for diagnosing ringworm:

1. Examination of the hair coat and skin
2. Wood's lamp examination
3. Direct examination of hairs under a microscope
4. Dermatophyte (fungal) culture

When cats, and especially kittens, come in to CP care, carefully inspect their hair coat and skin for lesions. Look for any areas of hair loss, scabbing or crusting, especially focal areas affecting the face, ears, feet and tail.

Perform a Wood's lamp examination of all suspicious lesions, making sure the correct procedure is followed and bearing in mind the limitations of this examination (see section titled: What are the details of the diagnostic tests that are used?). Only 50 per cent of dermatophyte species fluoresce and some non-fungal materials will fluoresce. Warm up the lamp five to 10 minutes before use and do not shine directly into the cat's eyes.

Ensure the vet screens for ringworm on the initial vet check. Further diagnostic testing (for example, fungal culture and microscopic examination) may be warranted (see section titled: What are the details of the diagnostic tests that are used?).

3. What action should be taken as soon as there is suspicion of ringworm?

3.1 Housing of suspect and confirmed cases

All suspect and confirmed cases of ringworm **MUST** be isolated immediately away from other cats/kittens. If this is not possible, at least try to keep separate from highest risk groups – that is kittens, pregnant queens, sick cats and elderly cats.

Ideally each cat or kitten should be housed individually. Kittens once weaned should be separated and housed individually.

If the cat is in a pen on its own, keep the cat in the sleeping area of the pen only. This is to reduce the contamination of the run with dermatophyte spores and limit the spread of spores in the draft or wind between pens. If housing singly is not possible and it is unreasonable to confine more than one cat in the sleeping area (dependent on pen type), then the daily cleaning and disinfecting must be even more thorough and extra vigilance must be maintained to prevent spread within the facility.

Clearly identify suspect and confirmed cats with a sign on the pen.

3.2 What to do with cats that have been in contact with a suspect or confirmed case of ringworm?

If possible, cats that have been in contact with a cat showing lesions or confirmed to have ringworm and that do not have lesions themselves should be housed separately from the suspect or confirmed case. A hair sample should be obtained and sent to the laboratory for culture before starting treatment.

3.3 Protective clothing

Protective clothing *must* be worn at all times while working with affected cats.

Protective clothing includes: theatre suit or disposable overalls, disposable apron, gloves, elbow protectors, disposable caps and over shoes. It is important to remember protective clothing should always be worn even while feeding affected cats.

Use new disposable clothing for each pen – change apron, gloves, elbow protectors between each pen and dispose of after use. **Do not** re-use.

Footbaths with a suitable disinfectant should also be used and should be changed or replenished daily.

3.4 Bedding and soft materials

Bedding used should be disposable – for example, old towels which can be thrown away.

Soft toys and scratching posts should be removed from the cat's environment and disposed of as soon as ringworm is suspected or diagnosed.

3.5 Litter trays

If possible use disposable litter trays and discard at least once daily. If disposable litter trays are unavailable, ensure that the standard litter trays are soaked separately with disinfectant and returned to the same cat.

3.6 Food and water bowls

Disposable food bowls should be used and discarded daily. Water bowls should be soaked separately in disinfectant, thoroughly rinsed and returned to the same cat.

3.7 Cleaning and handling

If possible have just one person delegated to deal with the ringworm cases. This person should not handle any other cats/kittens or even go into the other areas where cats are housed.

To reduce the risk of spreading the disease, cats that have ringworm should be dealt with last after all the other cats have been cared for.

Pens should be thoroughly cleaned and disinfected daily.

Vacuum and disinfect radiators, vents and floors daily. Vacuum bags should be disposed of carefully, ideally by burning or as infectious waste. Sweep all debris into the litter tray and dispose of from there.

Cleaning cloths should be disposed of daily.

All materials that will be disposed of from the pen should be placed in a plastic bag while still in the pen. Protective clothing should be placed in the bag as the pen is vacated and the bag should be sealed before removing it from the pen.

The preferred disinfectants to be used for cases of ringworm are bleach and Virkon.

If using bleach, all surfaces of the pen must be cleaned with detergent first and then disinfected with bleach diluted at 1:32 while cats are housed in the pen. The contact time for bleach should be 15 minutes and the area must be rinsed off with clean water afterwards.

Mop, bucket, sweeping brush, dustpan and brush should all be soaked in 1:10 bleach solution, or another suitable disinfectant, after use.

All the materials/equipment should be kept with the infected cat(s) and not taken to any other location.

Do not groom ringworm-infected cats.

3.8 Waste disposal

Although there is currently no legal requirement, dispose of all protective clothing, bedding, soft materials, soiled litter etc. as infectious waste (so that it will be incinerated). If disposal as infectious waste is not possible, place everything in a separate black bag and when finished tie up the bag securely and dispose of carefully.

3.9 After treated cats have left the pen

Once mycological cure has been achieved, the cat(s) can be moved to the homing wing in an Adoption Centre or homed from the pen or indoor fostering room in a fostering environment.

Discard all contaminated bedding, toys etc., and dispose of carefully as infectious waste.

Clean and disinfect all non-porous surfaces where the cat has been housed thoroughly with 1:10 bleach solution (leave for a minimum of 15 minutes), or other suitable disinfectant, and rinse thoroughly. Repeat daily for five days.

Thoroughly clean and disinfect any exposed radiators, skirting boards and vents daily for five days. If vacuuming, be sure to dispose of the vacuum bag daily.

If possible, steam clean or fog the area where the cat has been housed, daily for five days.

4 How is ringworm treated?

The vet will prescribe the appropriate treatment for ringworm. Cats *must not* be rehomed until mycological cure is achieved (see section titled: How is successful treatment determined and when is the cat ready to be homed?). When to start treatment will be decided by the attending vet.

4.1 What is the recommended treatment protocol?

1) *Adult cats with lesions suspicious of ringworm*

A sample for culture should be taken for all cats (adults and weaned kittens) showing lesions typical of ringworm before any treatment is given. In general, if the cat is showing lesions typical of ringworm or if there is a history of ringworm exposure in conjunction with clinical signs, treatment with Itrafungol may be started before the results of culture done by an external lab are obtained. However, the vet may want to delay starting treatment until the culture result comes back.

The exception to this treatment protocol is that a pregnant or lactating queen with kittens cannot be treated with Itrafungol. If a queen is feeding kittens and she alone or she and the kittens have ringworm, she cannot be treated until the kittens are weaned because Itrafungol is secreted in the milk and so there is a potential risk of overdosing. Thus, it is recommended that treatment of the queen with Itrafungol is delayed until the kittens are weaned. The kittens should be weaned early at five or six weeks of age and separated from the queen before she is treated. If the queen is severely affected, she can be treated topically with Imaverol to decrease the spread of spores in the environment and to reduce her discomfort. If the queen is showing no lesions two weeks before weaning, it may be worthwhile to take a coat brushing sample for culture to confirm whether the cat is still infected.

2) *Unweaned kittens with lesions suspicious of ringworm*

A sample for culture should be taken for all unweaned kittens showing lesions typical of ringworm before any treatment is given. If they are greater than 10 days old, treatment with Itrafungol can be started. If they are less than 10 days old, treatment must be delayed until they are greater than 10 days old.

In the case of a litter of kittens with queen where the kittens or the queen are severely affected, the kittens can be treated with Itrafungol if they are over 10 days old, bearing in mind that they may take longer to cure because they are in contact with a potentially infected queen.

3) Cats that have been in contact with a suspect or confirmed case of ringworm, but aren't showing any signs

Cats (adults and weaned kittens) that have been in contact with a suspected or confirmed case of ringworm that are not showing any skin lesions should be separated from the affected cat(s). A coat brushing sample for culture should be taken before any treatment is given and a second sample one week later. If either culture result is positive, treatment with Itrafungol should be started as soon as any positive result is obtained. If both culture results are negative, they should be homed as normal.

4) Unweaned kittens that have been in contact with a suspect or confirmed case of ringworm, but are not showing any signs

If unweaned kittens are not showing any lesions they should be weaned as soon as possible and separated from the queen. They should then be treated as an in-contact (as in point 3 above) by taking a coat brushing sample for culture before any treatment is given and a second sample one week later. If either culture result is positive, treatment with Itrafungol should be started as soon as any positive result is obtained. If both culture results are negative, they should be homed as normal.

4.2 What are the details of the different treatments that are available?

Itrafungol (Itraconazole)

This is Cats Protection's preferred treatment. It is licensed to treat *Microsporum canis* in cats and is an effective medication that is administered orally. A course of treatment lasts five weeks with dosing on alternate weeks. Itrafungol continues to work for two weeks after the last day of treatment. If a further course of treatment is required, it is advised to wait two to three weeks before restarting treatment. Itrafungol is safe to use in kittens from 10 days old.

Imaverol (Enilconazole)

This product is not currently licensed for use in cats. However, it can be used 'off-licence' to treat *Microsporum canis* or *Trichophyton sp.* if prescribed by the attending vet in the treatment of ringworm in cats. It can be used in pregnant and lactating animals. Unweaned kittens should not be treated with Imaverol. Treatment involves spraying the animal with a diluted solution of the product. It can reduce spread within the environment and increase recovery time. It should not, however, be used as the sole treatment.

When using Imaverol, the operator must wear suitable protective clothing including impermeable rubber gloves and safety glasses. When using this product as a spray, wear a mask to prevent inhalation. It is also recommended that cats are fitted with an Elizabethan collar following bathing until the coat has dried. If a queen with kittens is treated, spraying product on the nipple area should be avoided and she should be kept separated from the kittens until her coat has dried.

Grisovin (Griseofulvin)

This product is *not* recommended by Cats Protection, as Itrafungol is now widely available. It is not licensed for use in cats and poses Health & Safety risks to people. Gloves *must* be used if medicating a cat with Grisovin (Griseofulvin).

Malaseb shampoo

This product can be used for shampooing cats. It is licensed as an aid in the treatment of ringworm due to *Microsporum canis* in the cat in conjunction with griseofulvin and thus, should only be used in conjunction with griseofulvin when treating ringworm. As Cats Protection does not recommend the use of griseofulvin, it also doesn't recommend the use of Malaseb. It is not advised to use Malaseb in conjunction with Itrafungol as Malaseb may reduce the effectiveness of the Itrafungol.

Lime Sulphur dip

This treatment is also not licensed for use in cats and must be sprayed on the cat twice weekly. Discuss with the attending vet whether this is an option.

Program (Lufenuron)

This product is not licensed for treating ringworm in cats. At one time it was thought that the oral form may have some benefit in the treatment of ringworm, but evidence for this is lacking and therefore Cats Protection does not recommend it.

Vaccination for ringworm

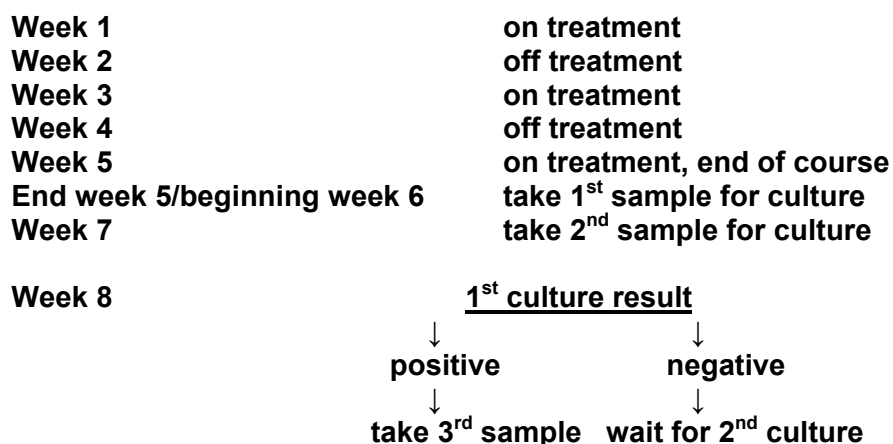
There is no vaccine available for ringworm in cats in the UK.

Clipping

It can be helpful, especially in the shelter environment, to clip the hair at least 6 cm around focal lesions. Sometimes the vet may recommend completely clipping cats that have multiple lesions or those with long or dense hair coats. Care should be taken when clipping to avoid traumatising the skin and a designated room should be used just for this purpose. Ideally this would be done at the veterinary practice. Vacuum the room thoroughly after use, taking care to dispose of the vacuum bag carefully, then disinfect the room with bleach solution (1:10) or other suitable disinfectant. Disinfect clippers and scissors carefully after use.

It is important to take the vet's advice on which cases are most appropriate for clipping, as clipping will increase the spores in the environment and therefore may increase the risk of spreading the disease.

4.3 Protocol for Itrafungol treatment and post-treatment culture



6. What if the initial course of treatment fails?

The initial course of treatment has failed when:

- 1) The first and second post-treatment cultures are positive (P,P)
- 2) The first post-treatment culture is negative, but the second one is positive (N,P)
- 3) The first post-treatment culture is positive, the second sample is negative, but the third one is positive (P,N,P)

When this happens the cat should start another full five-week course of treatment with Itrafungol and the environment where the cat is housed should be assessed. If the cat is not housed individually, it should be moved to a pen on its own. The cleaning and disinfectant protocol should be reviewed to ensure there are no breaches in biosecurity. Topical treatment with Imaverol could also be considered.

If the cat still has skin lesions when starting the second course or if the first two post-treatment cultures were positive, further culture samples should not be taken until the end of the second course of treatment.

7. What are the details of the diagnostic tests that are used?

7.1 Wood's lamp examination

Indications

An ultraviolet Wood's lamp examination may be useful as a screening tool where *Microsporum canis* infection is suspected. Cats with skin disease who present with hair loss as the primary problem are the most likely candidates. A positive Wood's lamp examination is only suggestive of an infection – confirmation of infection requires fungal culture and microscopic examination of the fungal colony. The Wood's lamp is most useful in cats with skin lesions – it can be a poor tool to monitor infection status or as a tool to screen cats for subclinical infections (has infection, but is not showing signs).

Background Information

The Wood's lamp is one of the most misused diagnostic tools in veterinary dermatology and it is important to understand the limitations of its use. It is an ultraviolet light with a wavelength of 253.7 nm filtered through a cobalt or nickel filter. When certain strains of dermatophytes infect hairs, fungal metabolites are produced that fluoresce bright green when exposed to this light. Unfortunately, the only species of importance in veterinary medicine which fluoresces under a Wood's lamp is *M. canis*. Not all strains of *M. canis* will fluoresce and, in fact, not all fluorescing strains will fluoresce on all hosts. The lamp must be allowed to warm up for five to 10 minutes before use to ensure the temperature dependent wavelength is stable. Infected hairs may need to be exposed to the light for several minutes before they begin to fluoresce.

Equipment

Wood's lamp

Technique

1. The lamp should be turned on five to 10 minutes before use.
2. The lamp should be held over the skin lesions for at least five minutes before making an interpretation. Positive hairs will glow a bright apple green colour. If there is any doubt about the fluorescence, glowing hairs should be plucked in the direction of growth and the end of the hair shaft examined under the Wood's lamp.

Dermatophyte growth is often heaviest in the hair follicle. These hairs can then be used for culture or direct examination under the microscope.

Artefacts

Only actively infected growing hairs will show positive fluorescence; positive fluorescence is not seen with scales or debris on the skin. False positive fluorescence may be seen in bacterial infections, which usually show a bluish-white fluorescence. Areas where sebum has accumulated will also give a false positive reaction, but the colour is a dull blue-green.

Interpretation

A positive Wood's lamp examination is only suggestive of a ringworm infection, not diagnostic. Treatment should not be initiated based upon this finding alone and a definitive diagnosis should be obtained via fungal culture. A negative Wood's lamp examination is inconclusive.

7.2 Direct examination of hair

Another screening tool is direct examination of hairs under the microscope. Hairs can be plucked in the direction of growth, placed on a microscope slide in some oil and examined under the microscope with a 10X lens. Infected hairs will be thicker and paler and fungal elements may be seen. If new methylene blue stain is added to the slide, infected hairs will absorb the stain. If direct examination of hairs is positive for ringworm, treatment can be started while awaiting culture results.

7.3 Dermatophyte culture

Indications

A dermatophyte culture is the 'gold standard' for diagnosing ringworm. It is indicated whenever a Wood's lamp examination or examination of the hair under a microscope is positive, but also in any cat with suspicious skin disease, whether fluorescing or not. Although finding fungal spores is a clear indication for anti-fungal therapy, it is important to identify the organism type by culture.

Background information

Dermatophytes are commonly cultured on either Dermatophyte Test Medium (DTM) or Sabouraud's dextrose agar. A colour indicator has been added as an aid in identifying dermatophytes: a red colour change is suggestive of a dermatophyte infection. In-house DTM is available in either glass jars or flat plates. Flat plates are preferred over glass jars containing DTM slants as they yield more accurate results.

Collecting a sample for sending to an external lab or for in-house culture

Equipment

- Forceps
- Toothbrush in original packaging (sterile)
- Dermatophyte test medium and/ or Sabouraud's dextrose agar or universal container or paper envelope or bag if sending to an external lab

Technique

- Hair should be plucked from the outer edge or margin of suspect lesions.
- Alternatively, coat brushings using a toothbrush can be carried out. This is particularly useful when collecting samples for culture from cats that have apparent clinical cure and no longer have any visible ringworm lesions. The toothbrush is

combed vigorously over the cat's hair coat for several minutes or until hairs are visible on the bristles. Special emphasis should be given to areas where lesions are present, particularly if they are Wood's Lamp positive.

- Samples (hair pluck or toothbrush) can be submitted for culture to an external lab or cultured in-house as described below.
- Samples being sent to an external lab must be placed into a universal container or paper bag, not a plastic bag.

Performing an in-house culture

- The fungal culture plate should be at room temperature before inoculating. This makes inoculation of the plate much easier.
- Individually plucked hairs should be firmly pressed on to the surface of the medium.
- For a toothbrush sample, the fungal culture plate is inoculated by gently embedding or repeatedly dabbing the toothbrush into the medium. It is important to be gentle or the fungal medium will stick to the bristles and be removed from the plate.
- Follow the instructions of the manufacturer of the fungal culture plate in terms of temperature, location, length of time to culture and interpretation.

Interpretation of a dermatophyte culture

Microsporum canis is best cultured at 25 degrees Celsius and is usually detected by one week after culture. However, the cultures are observed and test results reported for up to two weeks after submission.

A positive fungal culture is diagnostic for the presence of infective spores and treatment is warranted. If samples have been properly obtained and cultured, a negative fungal culture is conclusive.

Ideally dermatophyte cultures should be performed at an external laboratory using the CP discount lab scheme. Samples can also be cultured in-house, but this is more prone to error. In order to determine that the cat is free from infection following treatment for ringworm, two consecutive negative ringworm cultures carried out at weekly intervals are required, with the first sample taken at the end of treatment.